

Malignant gastrointestinal stromal tumor (GIST) of the jejunum: the mysterious complex presentation

Parvez Mujawar¹, Dhiraj B Nikumbh², Kishor H Suryawanshi², Poonam S Pagare², Rajesh Thakur³

¹Department of Surgery, Shri Bhausaheb Hire Government Medical College, Dhule, Maharashtra, India.

²Department of Pathology, ACPM Medical College, Dhule, Maharashtra, India.

³Department of Pathology, Shri Bhausaheb Hire Government Medical College, Dhule, Maharashtra, India.

Correspondence to: Dhiraj B Nikumbh, E-mail: drdhirajnikumbh@rediffmail.com

Received February 25, 2015. Accepted March 4, 2015

Abstract

Gastrointestinal stromal tumors (GISTs) are malignant and rare form of soft tissue sarcoma of the digestive tract. The incidence of GIST is very low (2 in 1,00,000) while jejunal GIST are extremely rare, accounting for 0.1%–3% of all gastrointestinal (GI) tumors. GIST is usually associated with abdominal pain, palpable mass, or GI tract (GIT) bleeding. About 5% of GI hemorrhages are ambiguous in nature, with GISTs being one of the cause. We herein present a case of 78-year-old man of malignant GIST of jejunum. The patient had mysterious and complex presentation of repeated per rectal (P/R) bleeding and melena, which resulted in hypotension. Upper GI endoscopy and colonoscopy showed normal findings. Despite the symptomatic treatment and investigation, the cause was obscure. Hence, emergency laparotomy was performed and diagnosis rendered. The highlight of this case was unusual nature of malignant GIST presented with obscure overt GI bleeding and diagnosed only at life-saving laparotomy with further confirmation on histopathology.

KEY WORDS: Gastrointestinal stromal tumors, jejunum, gastrointestinal neoplasms

Introduction

Gastrointestinal stromal tumors (GISTs) are uncommon tumors accounting for 1% of all gastrointestinal tract (GIT) neoplasms.^[1] GISTs are rare form of soft tissue sarcoma of the GIT. Two-third of the GISTs are located in stomach while one-fourth develop in the small intestine.^[2,3] The incidence of the GIST is very low, that is, 2 in 1,00,000, while jejunal GIST is extremely rare accounting for 0.1%–3% of all GIT tumors.^[4]

GISTs are generally asymptomatic; however, they can also present as abdominal pain, bleeding, or mechanical obstruction. Exophytic growth of these tumors has been


reported in 18%–30% of the cases.^[5] The most common clinical presentation of GIST is GI bleeding (may be acute or chronic) related to mucosal erosion in approximately 50% of the cases.^[6]

We herein describe a case of 78-year-old man presented with repeated episodes of per rectum bleeding and melena leading to hypotension. In spite of investigations, no pathology was found. Hence, life-saving laparotomy was performed. At laparotomy, jejunal mass with extensive hemorrhagic and necrotic areas noted along with extensive peritoneal metastasis. Histopathologically, this mass proved as malignant/high-grade GIST. We present this case in view of its mysterious and complex presentation with unusual gross and microscopic features.

Case Report

A 78-year-old man presented to the surgical OPD of our hospital with chief complaints of repeated history of per rectal (P/R) bleeding and melena since 4–5 days. There was no history of fever, vomiting, or hematemesis. The repeated P/R bleeding resulted in hypotension in the patient. It was treated

Access this article online

Website: http://www.ijmsph.com	Quick Response Code: 
DOI: 10.5455/ijmsph.2015.25022015228	

International Journal of Medical Science and Public Health Online 2015. © 2015 Dhiraj B Nikumbh. This is an Open Access article distributed under the terms of the Creative Commons Attribution 4.0 International License (<http://creativecommons.org/licenses/by/4.0/>), allowing third parties to copy and redistribute the material in any medium or format and to remix, transform, and build upon the material for any purpose, even commercially, provided the original work is properly cited and states its license.

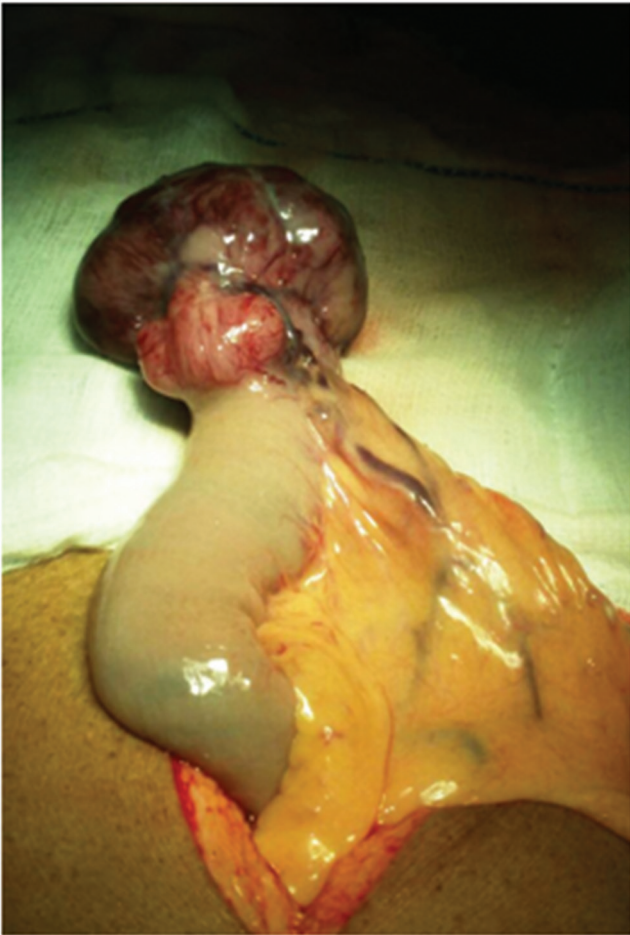

Figure 1: Intraoperative photograph of jejunal mass protruding through wall with congested, gray-brownish appearance.

conservatively with intravenous fluids, blood transfusion, and terlipressin. In spite of the treatment, the patient showed repeated P/R bleeding. There was no significant personal or family history. Upper GI endoscopy and colonoscopy showed normal findings. Local examination revealed tenderness over the abdomen with patient in hypotensive shock. Hematological examination revealed iron-deficiency anemia, and other serological and biochemical examination was within normal limits. Patient symptoms were not relieved in spite of the investigation and treatment; hence, emergency life-saving laparotomy was performed with proper precautions. Intraoperative findings revealed a large mass protruding through the jejunal wall with extensive areas of hemorrhage and necrosis [Figure 1] along with multiple whitish peritoneal nodules s/o metastasis. The mass was excised and end-to-end anastomosis done. The resected specimen was sent for histopathological examination. Postoperative period was uneventful, and patient was good on regular follow-up and sent for higher center for chemotherapy.



Figure 2: Gross photograph of excised well-circumscribed tumor mass with gray-blackish appearance and clear surgical margins.

Gross Examination

The received excised specimen of jejunum measured 8 cm in length and tumor mass attached to the serosal aspect measured $7.5 \times 5 \times 4$ cm. E/S of the tumor mass was well circumscribed and gray brown in color and appeared protruding through serosa and attached to it [Figure 2]. C/S of the mass showed variegated appearance with large areas of hemorrhage and necrosis and gray-whitish viable tumor mass with firm areas [Figure 3]. The tumor was seen infiltrating up to serosa and at place up to mucosa. Both the surgical margins and mesentery were free from tumor. In addition, the peritoneal lesion received measured $4 \times 3 \times 2$ cm. E/S and C/S: multinodular, gray whitish.

Light Microscopy

Multiple sections studied showed wall of the small intestine and a tumor. The tumour was seen arising from the muscularis propria and infiltrating up to the serosa [Figure 4]. At places, tumor was invading the mucosa also. The tumor was composed of two cell populations with predominance of plump spindle cells arranged in short fascicles, storiform, whorls, sheets, and nests. The individual tumor cells were slightly elongated fusiform, having moderately pleomorphic vesicular nuclei with occasional prominent nucleoli with pale eosinophilic cytoplasm [Figure 5]. In areas, the tumor showed round epithelioid cell predominance with vacuolated to clear cytoplasm with well-defined cell membranes. Focal skeinoid

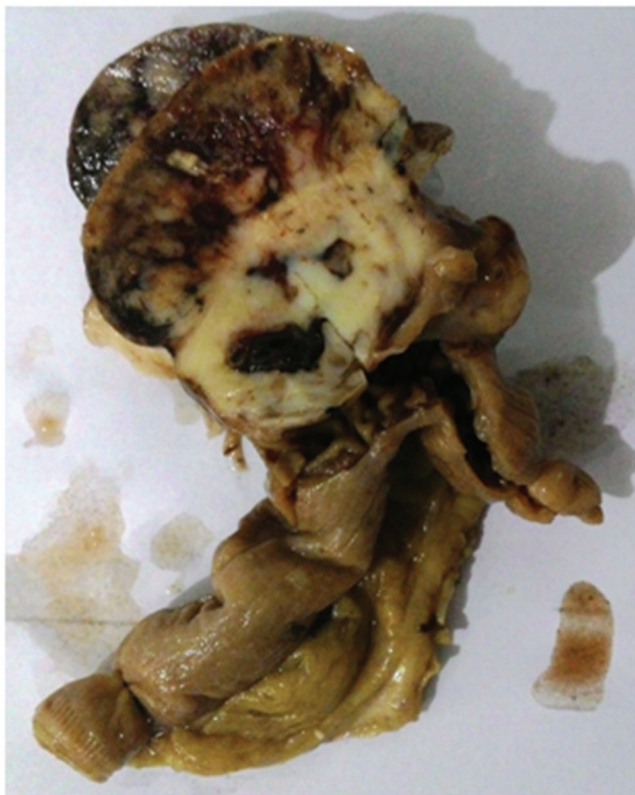

Figure 3: Cut section of the tumor mass with variegated appearance and destruction of the wall.

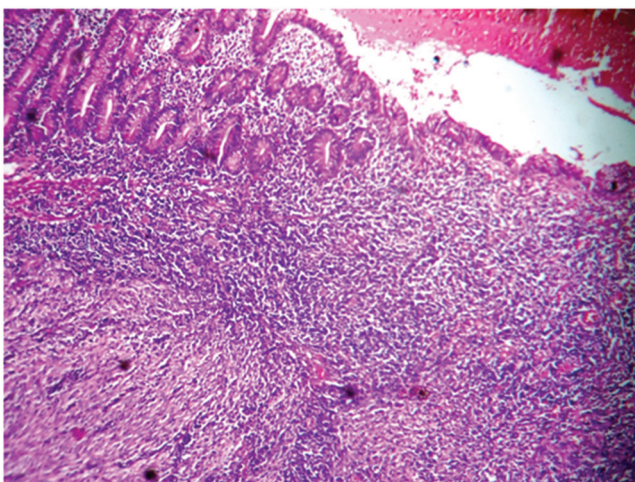


Figure 4: Photomicrograph of GIST arising from muscularis propria and reaching up to mucosa of jejunum leading to ulceration (H&E, ×100).

fibers/collagen was also evident. Large areas of hemorrhage and necrosis were noted. Tumor showed moderate (3–6/hpf) mitotic figures. Serosa showed inflammatory exudates. Both the peripheral surgical margins were free from tumor. Section from peritoneal metastatic lesion showed tumor nodules as

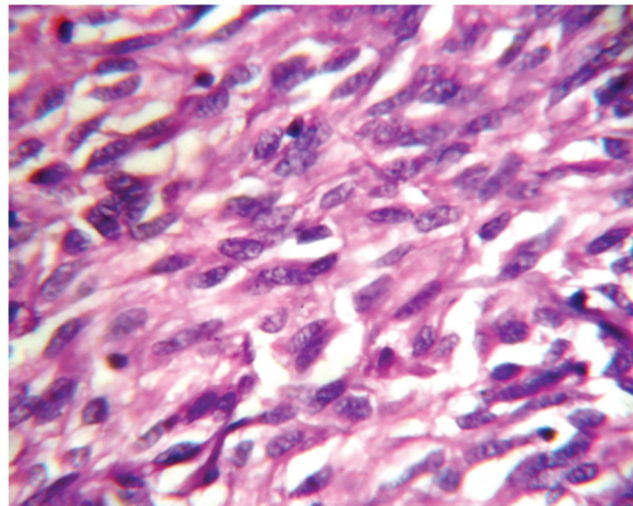


Figure 5: Photomicrograph showing plump spindle-shaped tumor cells arranged in fascicles with fusiform tumor cells having moderately pleomorphic nuclei (H&E, ×400).

described earlier. The final histopathological diagnosis was given as high-grade/malignant GIST of jejunum with peritoneal metastasis.

Discussion

GISTs are the most common mesenchymal tumor of the GIT but the least common of small intestinal neoplasms.^[7] Obscure GI bleeding may account for approximately 5% of all GI bleeding and is frequently because of a lesion in the small bowel.^[7] Angiodysplasia is the most frequent cause of midgut bleeding in approximately 70% of the cases. Small bowel tumors may be found in 10%–20% of cases of obscure GI bleeding.^[8]

The predominant site of the GISTs is the stomach (60%–70%), followed by the small intestine (25%–35%) and less common than 5% in rectum, esophagus, omentum, and mesentery.^[2,7] Within the small intestine, 17.7% are in duodenum, 47.6% in the jejunum, and 34.7% in the ileum.^[2] The clinical presentation depends on the size of the tumor. Small GIST less than 2 cm are symptomatic and incidentally detected at laparotomy or in endoscopy.^[2] The features of larger tumors include vague abdominal discomfort, acute/chronic GI bleeding, intestinal obstruction, or altered bowel habits.^[2] Very large GISTs presenting as exophytic palpable masses that are likely to be malignant.^[2] However, GISTs presenting with perforation and peritonitis is extremely rare phenomenon.^[9] In our case, only P/R bleeding and melena was the symptoms. Nowadays, GISTs may be defined as morphologically spindle cells, epithelioid cells, or occasional pleomorphic mesenchymal tumors originating from interstitial cells of Cajal or related stem cell expressing CD-117/C-kit protein in 95% of the cases regardless of the site of origin, histological appearance, and biological behavior.^[10]

Grossly, GISTs are usually unencapsulated but well-circumscribed masses. The cut surface shows a whorled fibroid-like or more fleshy with variegated appearance. Large lesions show cystic degeneration or central necrosis. Ulceration of the overlying mucosa is common.^[9] Majority (70%–80%) of the GISTs present with predominant histological pattern of a spindle cell tumor with a fascicular or storiform growth pattern.^[10] About 20%–30% of tumors are predominantly composed of large-round or polygonal epithelioid cells with abundant eosinophilic to clear cytoplasm.^[10] Mixed spindle and epithelioid tumors are common. These features were seen in our case with skeinoid fibers, which were noted in jejunal GIST predominantly.

GIST can be distinguished from the true smooth muscle tumors and Schwannomas of the GIT.^[11] The other differential includes intra-abdominal fibromatosis, inflammatory fibroid polyp, paragangliomas, and metastatic malignant melanoma. Histologically, we can easily distinguish GIST from these entities and further support by immunohistochemistry.^[11]

The spontaneous treatment of small intestinal GIST is surgical resection. Imatinib mesylate is the standard regimen of the tumor for metastatic or inoperable masses.^[2,11] Small intestine GISTs are more destructive than those of stomach, with approximately 40%–50% of the small bowel GISTs showing malignant behavior compared with 20%–25% of the gastric GISTs.^[11] Complete *en bloc* resection with clear surgical margins is the primary treatment for localized GISTs.^[11]

Jejunal GISTs are rare clinical entity, accounting for only 0.1%–3% of all GI tumors. They are more aggressive than those in stomach; hence, proper diagnosis by histopathology is always warranted.

Conclusion

The aim of this case was to focus on the unusual nature of jejunal GIST, which presented with obscure and overt GI bleeding and only diagnosed at laparotomy. This case highlights the diagnostic difficulty and unusual presentation of jejunal GIST. The mysterious and complex presentation may be kept in mind in view of its more aggressive and malignant nature.

References

1. Joensuu H. Gastrointestinal stromal tumor (GIST). *Ann Oncol* 2006;10:280–6.
2. Miettinen M, Sobin L, Lasota J. Gastrointestinal stromal tumors of the stomach: a clinicopathologic, immunohistochemical, and molecular genetic study of 1765 cases with long-term follow-up. *Am J Surg Pathol* 2005;29(1):52–68.
3. Goldblum JR. Gastrointestinal stromal tumors: a review of characteristics morphologic, immunohistochemical, and molecular genetic features. *Am J Clin Pathol* 2002;17:49–61.
4. Kramer K, Siech M, Sträter J, Aschoff AJ, Henne-Bruns D. GI hemorrhage with fulminant shock induced by jejunal gastrointestinal stromal tumor (GIST) coincident with duodenal neuroendocrine carcinoma (NET) + neurofibromatosis (NF)—case report and review of the literature. *Z Gastroenterol* 2005;43(3):281–8.
5. Nilsson B, Sjölund K, Kindblom LG, Bümbling P, Nilsson O, Andersson J, et al. Adjuvant imatinib treatment improves recurrence-free survival in patients with high-risk gastrointestinal stromal tumours (GIST). *Br J Cancer* 2007;96(11):1656–8.
6. Ludwig DJ, Traverso LW. Gut stromal tumors and their clinical behaviour. *Ann J Surg* 1997;173(5):390–4.
7. Sama JJ, Mustardb R, Kandela G, Gardinerc G, Ghaffarc H, Kirpalanid A, et al. Kima colonoscopy leads to a diagnosis of a jejunal gastrointestinal stromal tumour (GIST). *Gastroenterol Res* 2011;4(6):277–82.
8. Cellier C. Obscure gastrointestinal bleeding: role of video-capsule and double-balloon enteroscopy. *Best Pract Res Clin Gastroenterol* 2008;22(2):329–40.
9. Jagtap SV, Nikumbh DB, Kshirsagar AY, Bohra A, Khatib W. Malignant gastrointestinal stromal tumor of the sigmoid colon with perforation and peritonitis—an unusual presentation. *Int J Health Sci Res* 2012;2(3):104–9.
10. Fletcher CDM, Berman JJ, Corless C, Gorstein F, Lasota J, Longley BT, et al. Diagnosis of gastrointestinal stromal tumors: a consensus approach. *Hum Pathol* 2002;33:459–65.
11. De Silva CM, Reid R. Gastrointestinal stromal tumors (GIST): C-Kit mutations, CD-117 expression, differential diagnosis and targeted cancer therapy with imatinib. *Pathol Oncol Res* 2003;9:13–9.

How to cite this article: Mujawar P, Nikumbh DB, Suryawanshi KH, Pagare PS, Thakur R. Malignant gastrointestinal stromal tumor (GIST) of the jejunum: the mysterious complex presentation. *Int J Med Sci Public Health* 2015;4:1168-1171

Source of Support: Nil, **Conflict of Interest:** None declared.